OSC | 10
Ohio Safety Congress & Expo

What to do when eye emergencies happen

422

Greg Rosenthal, MD

Thursday, April 1, 2010 9:15 to 10:15 a.m.

Get a Vision if you can

- Not always easy or necessarily reliable
  - Due to head injury, drugs, alcohol, shock, panic
  - NEVER write off an eye because of no light perception "NLP" at the outset
- Light perception>>Hand Motions>> Counting Fingers>>Vision Card or Chart

Is it really NLP?

- If a patient is traumatized, any significant decrease in vision may be interpreted as "I can't see *anything*."
- Could seem "NLP" from surface blood, hyphema, vitreous hemorrhage, decreased sensorium, lots of things.
- Is the eye blown apart? If not, best not to believe NLP or use it as a basis for not trying to save the eye.

Pupil reaction

- Look for Afferent Pupillary Defect (APD)
- "Reverse" APD if you can't asses the injured eye
- Efferent pupillary defect
  - Blown pupil from iris or ciliary ganglion trauma
- Neurologic pupil
  - Herniation
  - Midbrain pupil
- Pharmacologic pupil

Inspection

- Anything to suggest open globe?
  - Sunken eye?
  - Obvious globe laceration?
  - Deflated eye on exam or CT?
- If so, cover eye with a Foxx Shield, keep the patient quiet, and call us.

Preventing Evisceration

- Don't push on the eye
- Don't make patient squint or clench eyes
- Prevent pain AND nausea
- If pain med causes nausea, you need to cover for this.
- Use parenterals at least until you know *everyone's* surgical plans

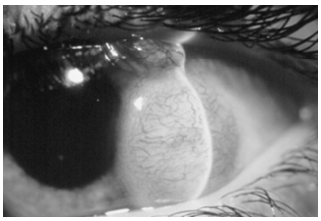

So, Some Dos and Don’ts

- Do:
- Get initial assessment of globe and ocular surface
- Keep patient quiet
- Cover eye
- Depending on nature of injury, get a CT with 2mm slices or better

- Don’t
- Press on eye or contribute to pain or nausea
- Pull anything out of the eye
- Get an MRI
- Try to close anything involving the canaliculus, the lid margin, or the levator

If the initial globe assessment is okay

- Carefully examine the eye and adnexa
- Lids
- Cornea
- Sclera
- Anterior Chamber
- Iris
- Lens

Lids

- Lacerations
- Foreign bodies
- Violation of tarsal plate, canaliculi, lid margin

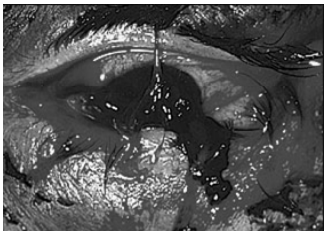

Lid Lacerations

- Often part of a complex facial laceration
  - If we want everything to match up, it has to be closed as one
- Swelling is often an issue
  - No problem for noncanalicular areas, but it is usual to pack canalicular laceration in cold, wet packing, give antibiotics and close with tubes in a couple of days
- Must preserve lid margin and canthus
- Restore levator integrity
- Line up skin folds, lid crease
- 5 or 6-0 nylon for surface
- Bring edges together DO NOT BUNCH the skin edges

Principles of Closure

- Line up the landmarks
- Don’t bunch the edges together
- No stretching or extras at the end
- Divide and Conquer
- Line up the landmarks
- Don’t bunch the edges together
- No stretching or extras at the end
- Deep layer with absorbable suture
- 5 or 6-0 nylon is fine for skin with small cutting needle.
- Can also use gut or Vicryl if you want
- Coat gut in antibiotic ointment to make it glide better

Deep laceration of brow and lids

Closure of deep tissue to bring skin and surface landmarks close

Note lack of tension and good approximation of tissues

Closing skin with small gauge nylon

Early Postop

Canalicular Repair

- Repair what you can initially
- Don't be a hero on the canaliculi
- Better to control swelling with ice, antibiotics, repair electively in 2-3 days

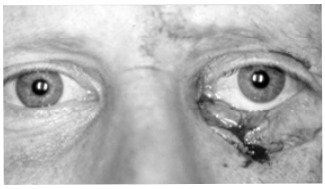

Canalicular repair

- Identify puncta
- Identify deep duct end
- Canalize and tie tubes in nasal cavity

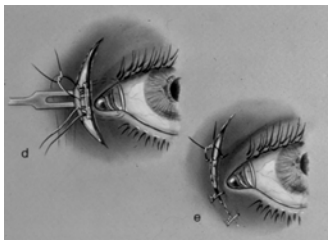

Identify outer punctum

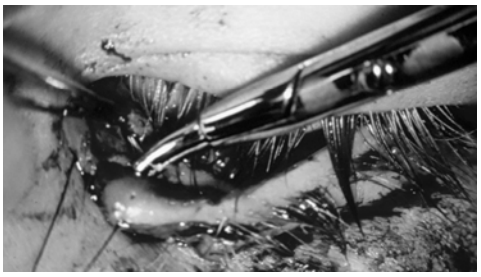

Identify the inner segment of the duct

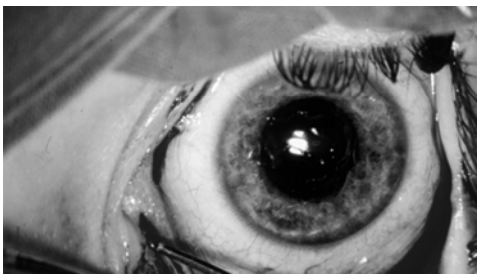

Cannulate the duct and tie tubes in nasal cavity

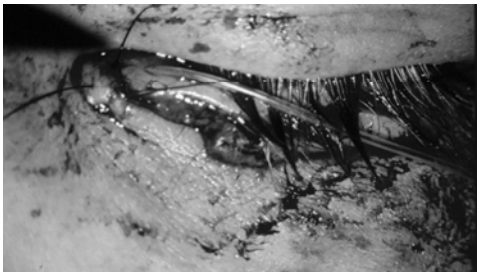

Tube in place

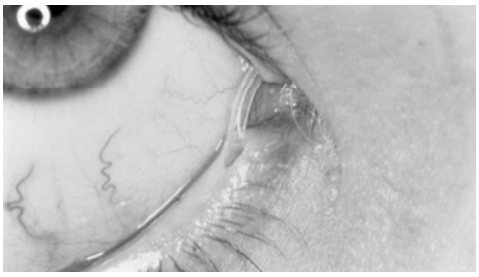

Tarsal Plate Laceration

- Need to restore inner tarsal plate surface and lid margin

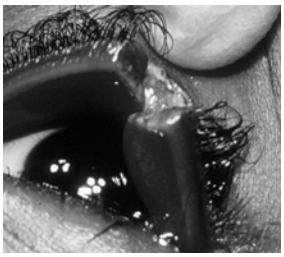

Principles of Tarsal Plate Closure

- Precisely realign and close plate from the outside
- Precisely realign grey line with a 6 or 7-0 nylon and leave ends VERY long so you can tape them to the eyelid
  - That way the stitch ends won't irritate or scratch the eye.
- Suture removal in 4 or 5 days.

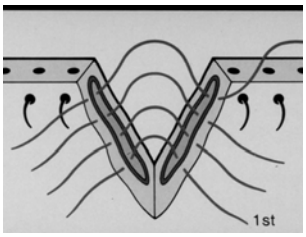

Closing the grey line

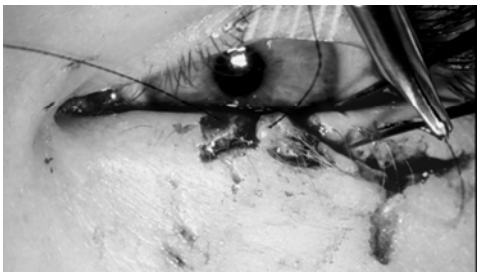

Ectropion from poor lid closure

Orbital Fractures

- Enophthalmos
- Motility Exam
  - Entrapment- forced ductions
- Swelling component
- CT evaluation
- Planning surgery, usually in 1 to 2 weeks after swelling subsides
  - Oculoplastics and ENT working together

Mechanism of Orbital Blowout Fracture

- Projectile, such as fist or ball, hits eye and displaces eye and orbital contents back, exploding the thin orbital floor or walls.
- May be accompanied by blunt injury (hyphema, irido- or retinal dialysis) or limbal or occult scleral rupture

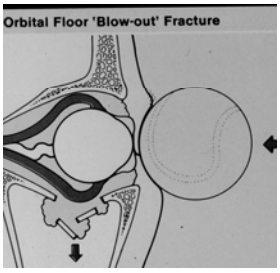

Inferior Rectus Entrapment

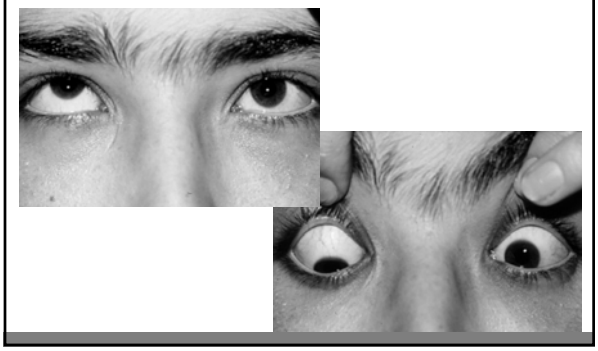

Corneal Exam

- Corneal Foreign Bodies
- Herpetic Keratitis
- Corneal Ulcers
- Lacerations and Limbal Ruptures
  - Restore anatomy with 9-0 and 10-0 nylon

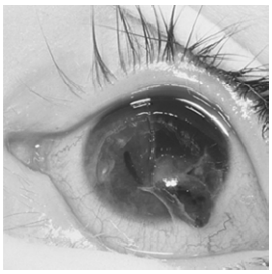

Corneal Foreign Bodies

- Metallic or nonmetallic
- Rust Rings
- Associated infection
- Easiest and safest to flick off metal with a 25 g needle, give antibiotic and NSAID drop and let us get the rust ring later
- Burr is okay but it is possible to do more harm than good

Metallic corneal FB with rust

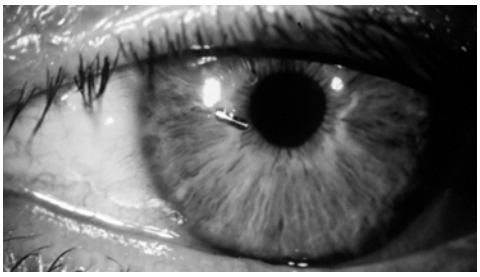

Use 25 g. needle as a shovel

Residual Rust Ring

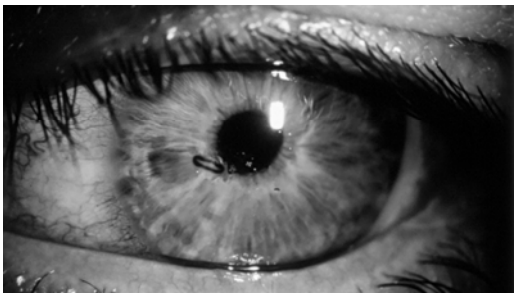

Herpetic Keratitis

- Usually HSV I or II
- Can be VZ
- Dendritic Ulcer best seen with Fluorescein staining
- Can be confused with a healing abrasion
- Treat with frequent Acyclovir (Viroptic)

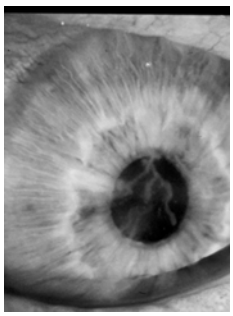

Bacterial Corneal Ulcers

- Trauma, Contact Lens Wear
- Watch for scleral thinning, descemetocoele
- “Sympathetic” Hypopyon
- Culture and treat with intensive broad spectrum antibiotics

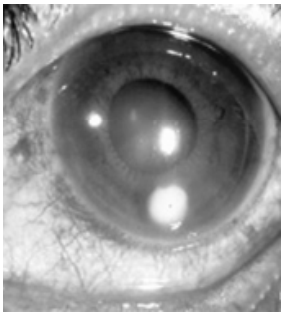

Fluorescein Staining of Corneal Ulcer

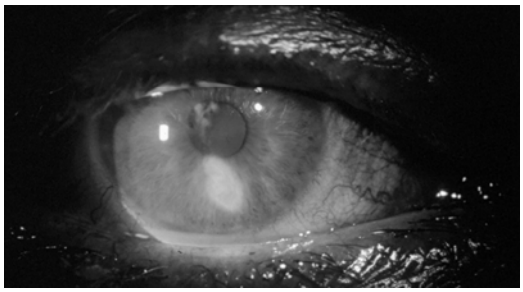

Corneal Ulcer with Sympathetic Hypopyon

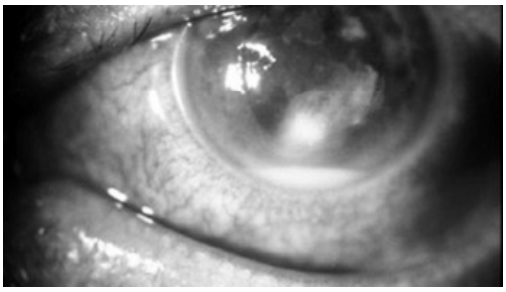

Corneal Ulcer with Descemetocoele (In a Dog)

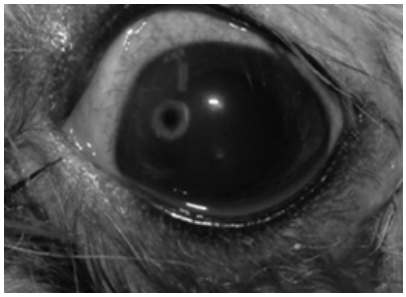

Clear Corneal Laceration

- May be obvious
- May be subtle
  - Look for irregular pupil, shallow chamber, iris transillumination or laceration, iris to wound, etc.

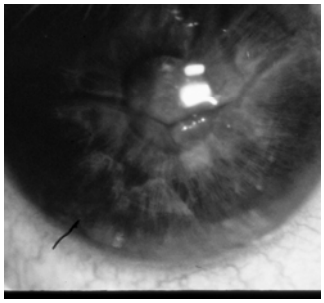

More Subtle Laceration

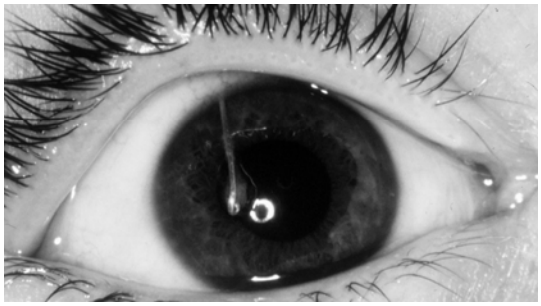

Iris Reposition and Closure with 10-0 nylon

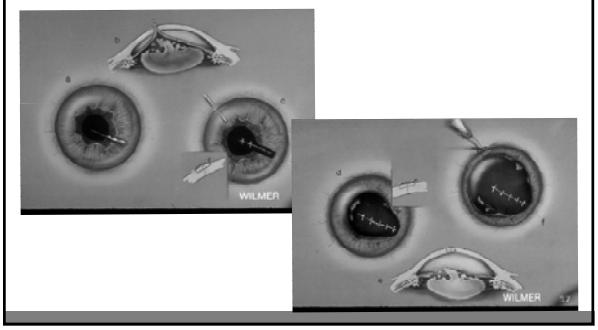

Proper Corneal Suturing

- o 10-0 or 9-0 nylon
- o *Nearly* full thickness bite
- o Even spacing
- o No stromal bunching

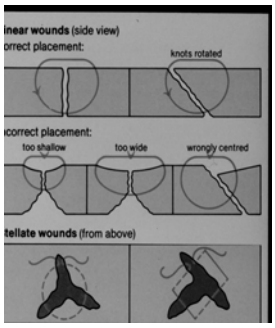

Limbal Rupture

- o Usually blunt injury
- o May be dehisced cataract wound
- o Corneal limbus is a weak point
- o Iris prolapse +/- pupil dragging
- o Close with 10-0 or 9-0 nylon +/- vicryl or rarely silk.

Scleral Rupture with Uveal or Retinal Loss

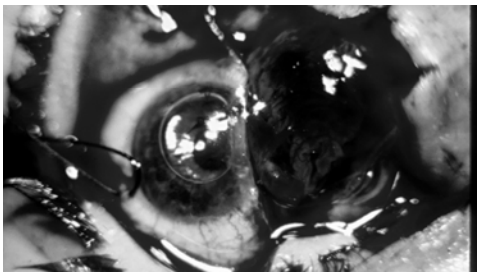

Scleral Lacerations

- o Exposed
- o Occult
- o Sharp or Blunt
- o Retina involved or not
- o Uveal or vitreous prolapse
- o Sew with 7-0 to 9-0 Vicryl or rarely silk

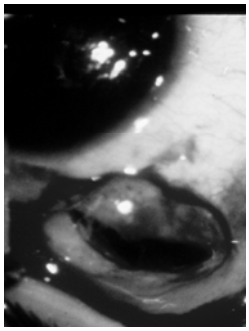

Sclera Repaired with Absorbable Stitch or Silk

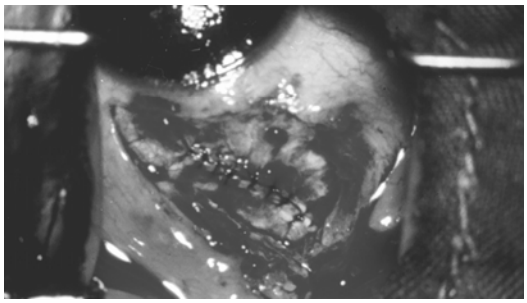

Anterior Chamber

- o Depth
- o Foreign body
- o Hyphema or infection

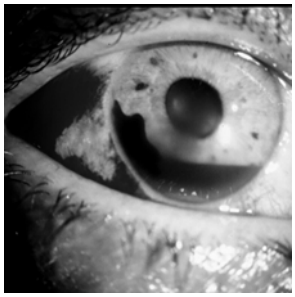

Foreign body on iris with inflammatory reaction

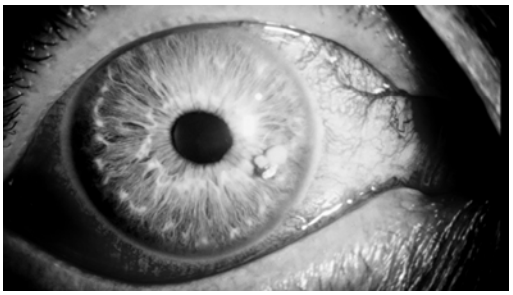

Stellate corneal laceration with flat chamber

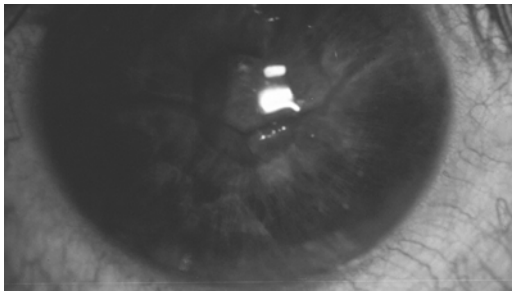

Corneal bisection with iris prolapse

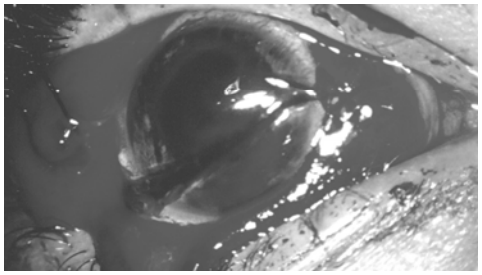

Anterior Chamber and Iris

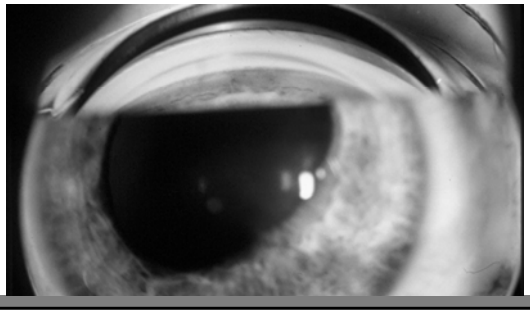

Bucket Handle Iridodialysis with Traumatic Cataract

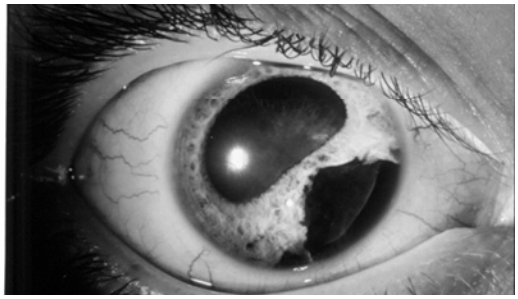

Angle Recession

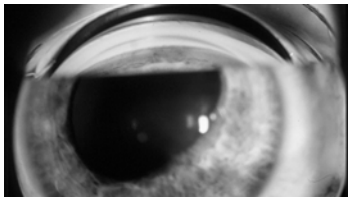

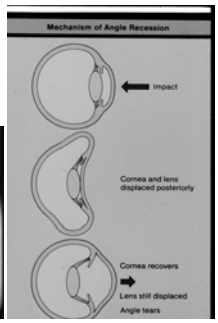

Iris

- o Pupil shape
- o Iris defects
- o Sphincter tears
- o Iridodilaysis
- o Bucket handle tears
- o Iris prolapse

Lens

- o Rupture
- o Dislocation or Subluxation
- o Lenticular foreign body
- o Natural or IOL

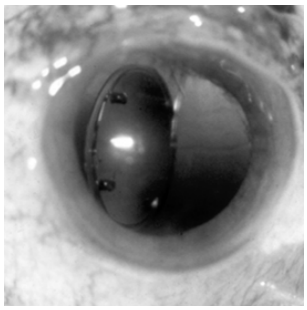

Lenticular Subluxation

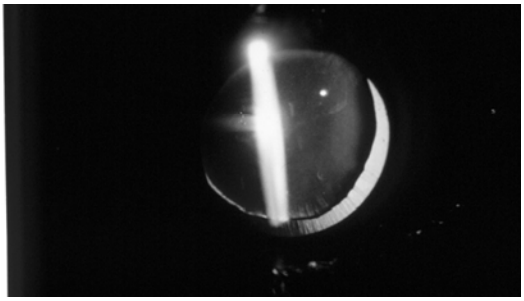

Subluxation Repair

Lenticular Foreign Body

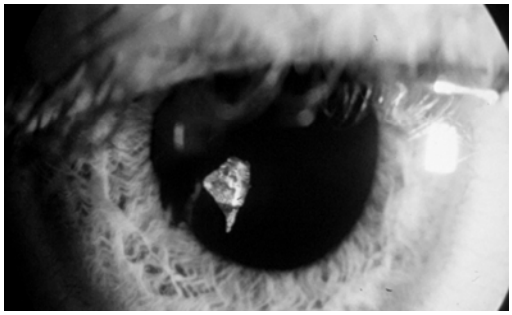

Iris Tear with Lens Dislocation

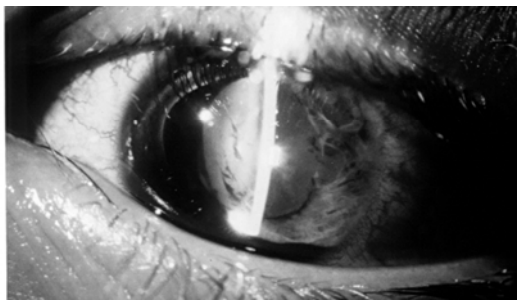

Posterior Lens Rupture

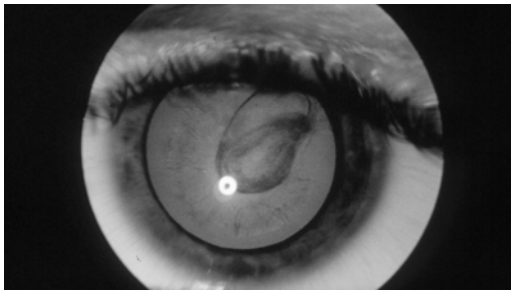

Vitreous

- Hemorrhage
- Foreign body
  - Metallic or not
  - Plant material
- Vitreous base tears

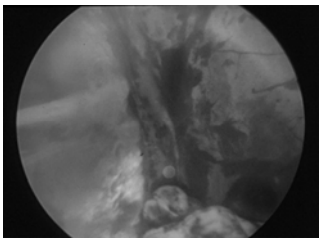

Intraocular Foreign Body

- Metallic can cause severe inflammation or impact damage
- Treated as a surgical urgency
- Iron is very neurotoxic
  - If you miss it, can cause optic atrophy and blindness
- Double perforation Injury

Localization of Foreign Body

- Skull film is a very sensitive screen
- CT better for localization
- Avoid MRI (metal!!)

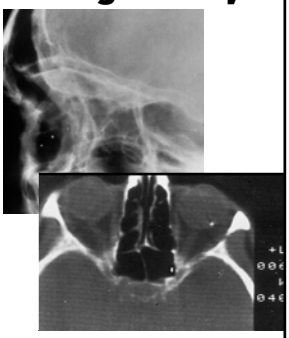

Iris Defect Suggesting IOFB

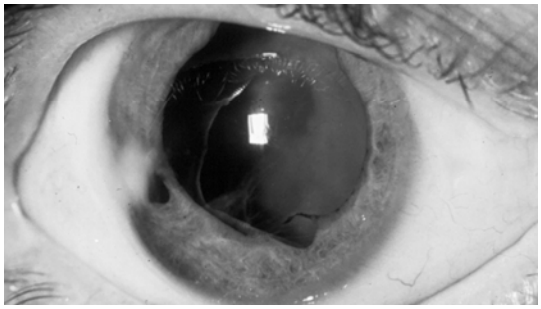

Metallic Foreign Body with Impact and Blood

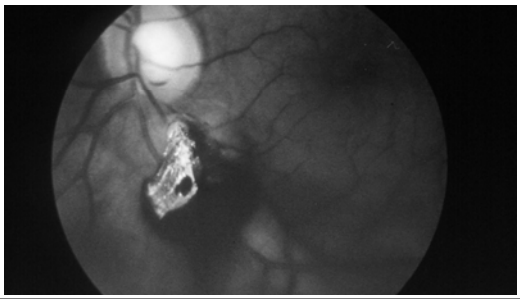

IOFB Later with Toxic Inflammation of Retina

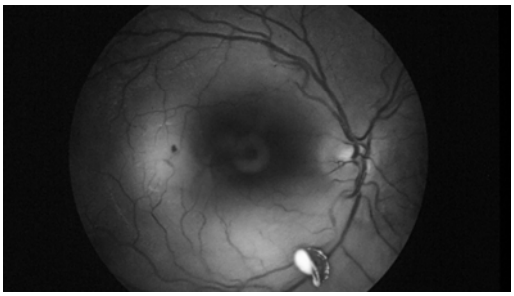

Double Perforation Exit Site with Surrounding Commotio

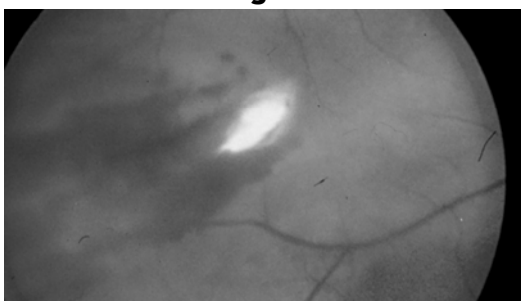

IOFB Removal Video

Retina and Optic Nerve

- Detachment
- Retinal tears
- Commotio
- Sclopeteria
- Choroidal Rupture
- Avulsion
- Tissue loss
- Double penetrating injuries

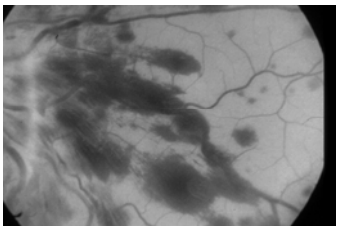

Retinal Commotio

- Contra-coup "concussion" of the retina
- Can be mild and self-limited or devastating
- Can be with or without other retinal injury

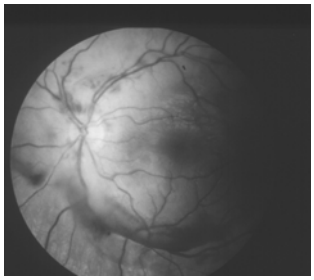

Retinal Sclopeteria

- Pulverization of retina from the shock wave of a high velocity projectile
  - Bullet
  - Fireworks
- Retinal detachment uncommon

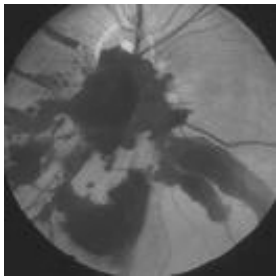

Late Sclopeteria Scarring

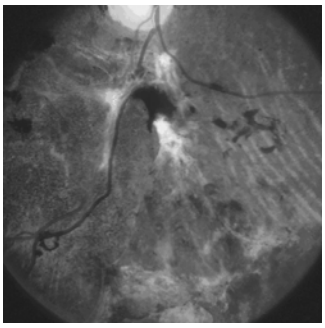

Choroidal Rupture

- o Blunt injury from eye wall distention
- o Acute stage
- o Late neovascularization
- o Optic Nerve Avulsion

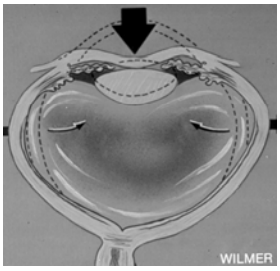

Acute Choroidal Rupture

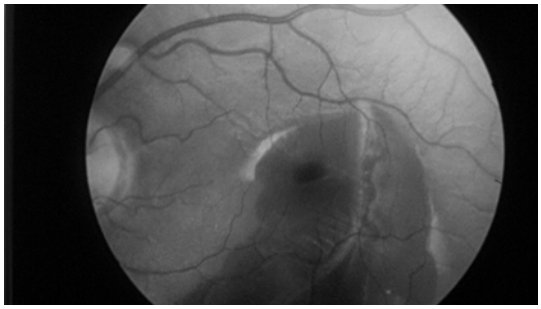

Late Choroidal Rupture

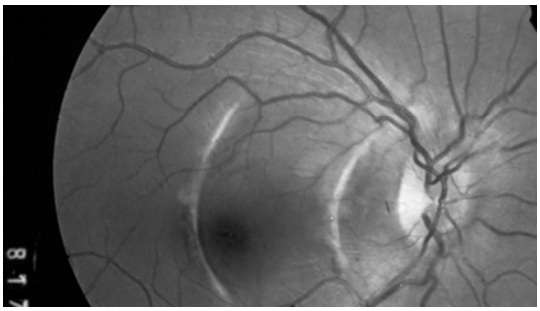

Acute Optic Nerve Avulsion

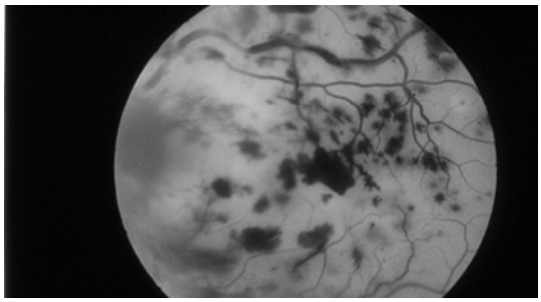

Late Optic Nerve Avulsion

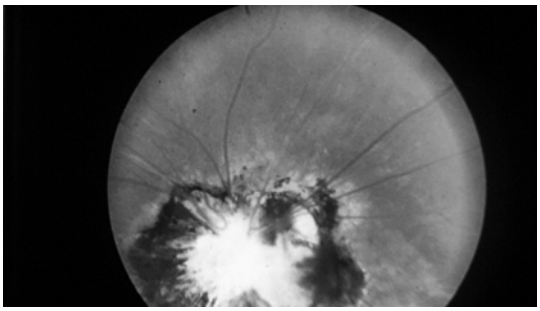

Retinal Detachment

- o Rhegmatogenous from open or blunt injury
- o Tractional after healing perforation

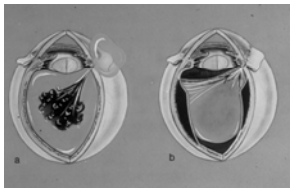

Rhegmatogenous Retinal Detachment

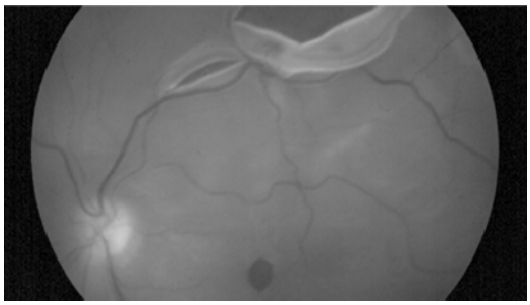

Traumatic Giant Retinal Tear

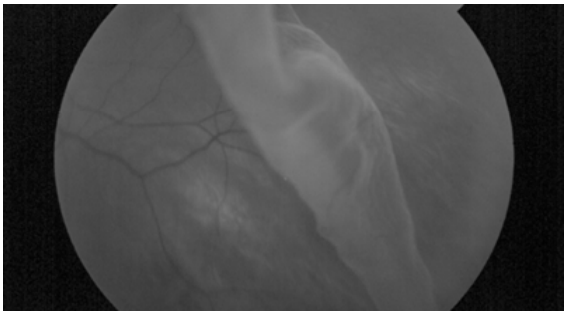

Repair of Giant Tear

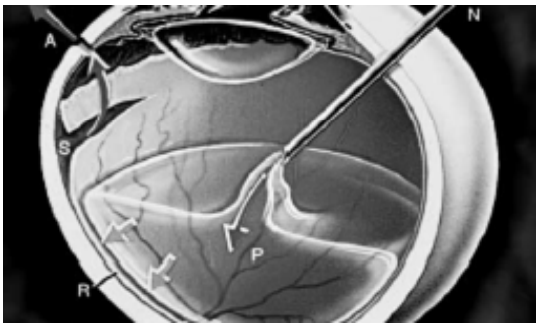

Repair of Tractional RD

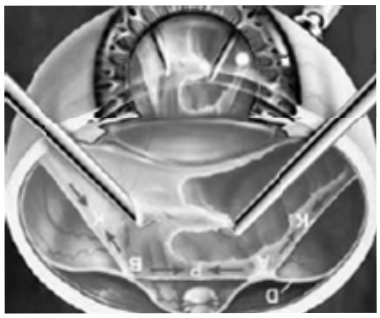

Double Penetrating Injury

- o Anterior injury can be deceptively mild
- o Depending on location of posterior perforation, prognosis can be good or awful
- o Repair surface anatomy acutely and do definitive vitrectomy within a week or two.

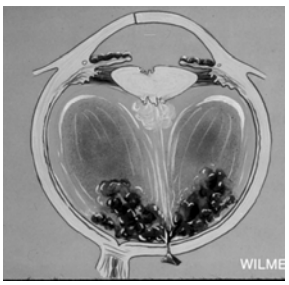

Acute Posterior Penetration

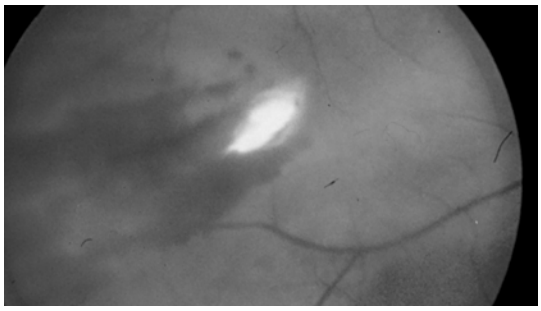

Late Posterior Penetration

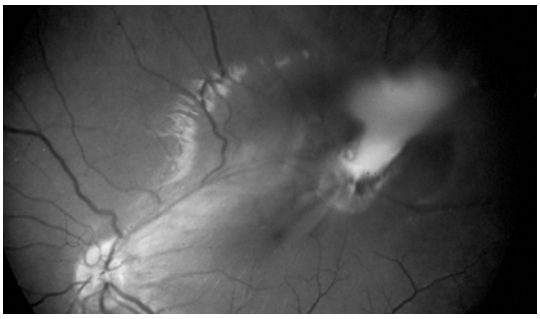

The Outlook

- It depends, but...
- It's not like it used to be
- We can fix most things
- It may not be as bad as it looks, so....
- Be careful, and never write anything off up front.